

Xive®

Scientific Summary

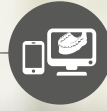

Comprehensive solutions for all phases of implant dentistry



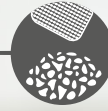
Professional and practice development

STEPS™



Digital planning

Simplant®



Regenerative solutions

Symbios®



Implants

Ankylos®
Astra Tech
Implant System®
Xive®



Restorations

Atlantis®



Welcome

Are you looking for information about the excellent results on primary stability and immediate loading when using the Xive implant system? Or do you want to explore different prosthetic solutions or learn more about the long-term clinical results? You will find the answers here, and much more.

This Scientific Summary provides a synopsis of the published key research findings supporting the Xive implant system. Each summary is based on facts retrieved from the original research article.

The Scientific Summary focuses on the following topics:

Primary stability and immediate loading	9
Prosthetic ease and versatility	15
Long-term clinical results	23
References	28

Summary by Dentsply Sirona Implants of facts retrieved from the original articles.

For a more comprehensive view of the documentation and research on our products, please refer to our Scientific Reviews. The Scientific Reviews are available for download at www.dentsplyimplants.com/science

To improve readability for our customers, Dentsply Sirona does not use ® or ™ in body copy. However, Dentsply Sirona Implants does not waive any right to the trademark and nothing herein shall be interpreted to the contrary.

Progress and Xperience

The development and launch of Xive in 2001 was based on a foundation of 25 years of experience in implant dentistry, including pioneering work and groundbreaking developments in the fields of immediate implant loading and implant surface structuring. Prosthetically, Xive is fully compatible with Frialit - offering a well structured line of color-coded abutments that has already set the standard since the 1990s.

In this tradition, Xive today stands for progressive and innovative solutions, surgical versatility and almost unlimited prosthetic freedom - an implant system that always strives to be one step ahead with the best solution for every patient.

2005

Introduction of CERCON zirconia abutments for superior esthetic results.



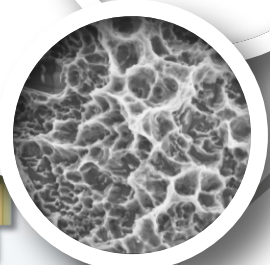
2002

Launch of the transgingival Xive TG implant.



1990

Development of the color-coded Friadent prosthetic range, successfully in use on Frialit since 1992 and on Xive since 2001.



2003

All Xive implants are provided with the innovative Friadent plus implant surface.

2003

Introduction of the Xive S 3.0 mm implant.

2001

Launch of the Xive implant system with subgingival Xive S implants, including the TempBase concept for immediate temporization.

1999

FRIALOC implants for easy and economical immediate loading concepts.

2009

Going CAD/CAM - Patient-specific implant suprastructures are introduced for Xive.



2012

Launch of the SmartFix concept - the prosthetic solution for full arch restorations on implants placed at an angle.



2013

More platform-switch options on Xive with introduction of new components.



2010

Atlantis patient-specific CAD/CAM abutments.



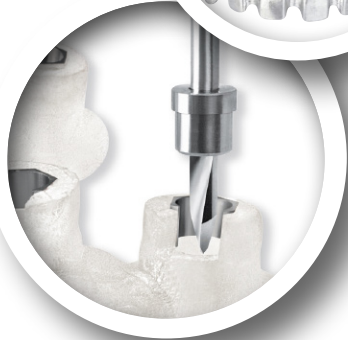2011

TitaniumBase - two-piece CAD/CAM abutments.



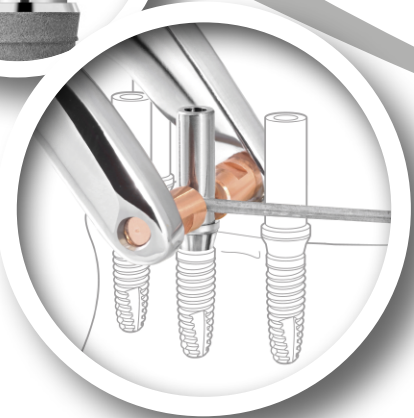
2009

Launch of computer-guided surgery for Xive, based on the market-leading Simplant software. Specially developed Sleeve-on-drill system for utmost precision and ease of use.



2014

The worldwide unique WeldOne concept is launched by facilitating stable and durable chairside solutions.





Clinical documentation on Xive[®] Implant System

The Xive implant system has been in clinical use for more than a decade. Its high surgical flexibility and prosthetic versatility are achieved by several features; a comprehensive implant and abutment selection, two different implant-abutment connections (internal hex and external square), and a flexible treatment protocol.

Published data shows that Xive implants is a safe and predictable treatment for indications such as: overdentures, single-tooth restorations, and fixed full/partial restorations. Furthermore, predictable results with implant survival rates ranging from 95 to 100% are reported, also in studies with immediately loaded implants, as well as for the 3.0 mm diameter implant. Moreover, there are published clinical results for implants immediately placed in extraction sockets and in grafted sites.

With the patented combination of a condensing thread design and a bone-specific preparation protocol for the

Xive implant, good primary stability can be achieved. Mean insertion torque values ranging from 28.7 to 40.1 Ncm, and mean ISQ values at implant insertion ranging from 61 to 74 have been reported. Similar values have been reported for the narrow, 3.0 mm, implant, as well as for implants placed in extraction sockets and grafted sites.

Several clinical studies report on mean marginal bone level changes around Xive implants after 1 year (range +0.1 to -1.1 mm), 2 years (range -0.9 to -1.0 mm), 3 years (range -0.53 to -1.37 mm), 4 years (-1.16 mm), 5 years (range -0.88 to -1.9 mm), and 10 years (-1.27 mm).

For a complete list of references supporting the Scientific Review "Clinical documentation on Xive implant system", please refer to www.dentsplyimplants.com/science

Versatility and ease

Depending on the clinical need, you can select the subgingival Xive S implant or the transgingival alternative Xive TG. The identical endosseous implant design even allows you to make your choice during the actual surgical procedure.

The prosthetic versatility of the system offers a practical solution for each implant case. Xive supports a large variety of prosthetic protocols. Where other implant systems may reach their limits, Xive makes the most of its advantages. Even highly complex cases can be mastered easily. Depending on each individual case and your preferences, you are free to select the preferred treatment concept.

Easy and versatile prosthetics

A range of prefabricated and patient-specific abutments provides versatility in prosthetics, both on implant and abutment level, including immediate restorations for any possible indication. Internal butt-joint connection with self-guiding properties and color-coded or laser-marked components support error-free workflow.

Bone care with platform-switch

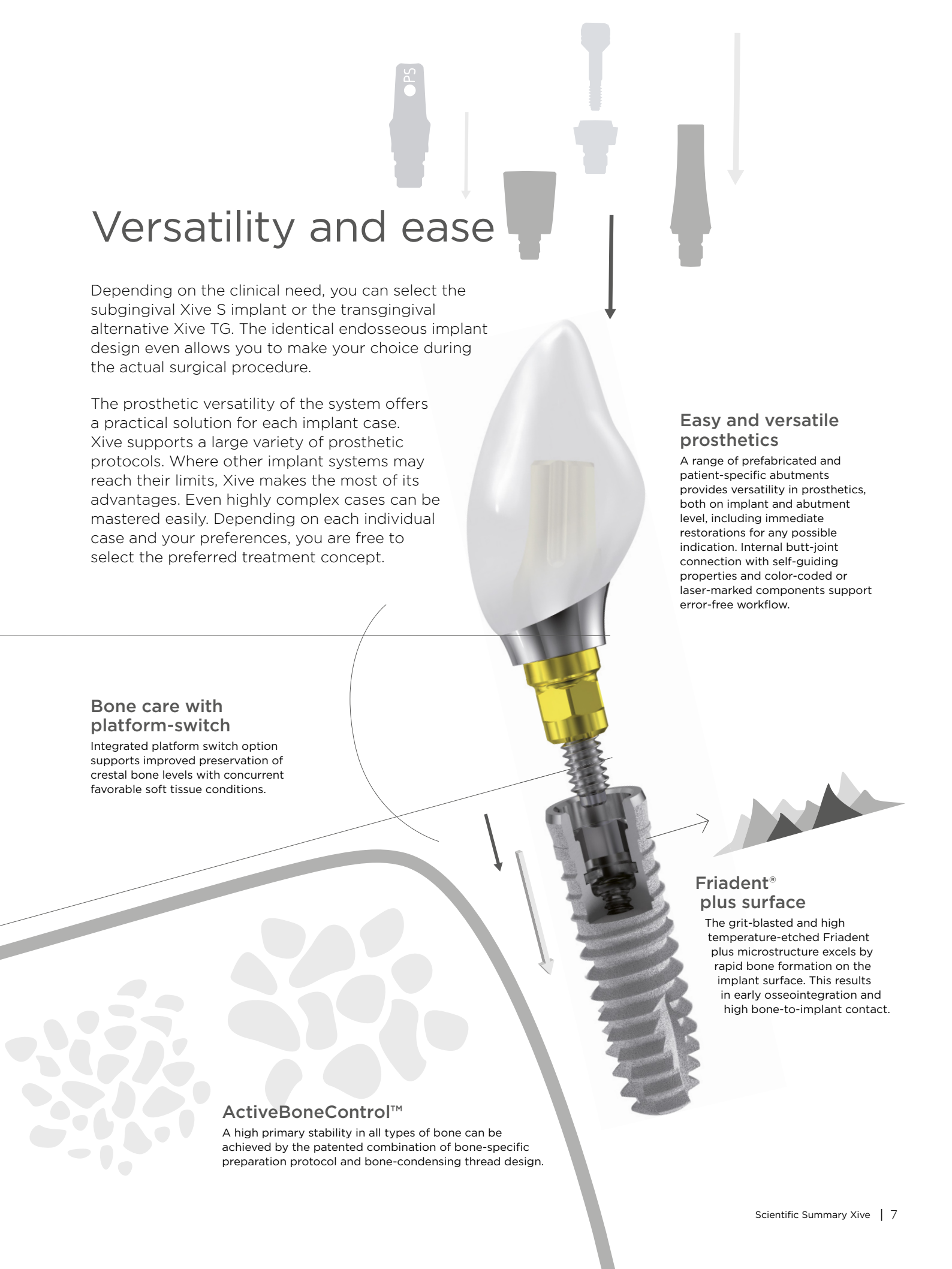
Integrated platform switch option supports improved preservation of crestal bone levels with concurrent favorable soft tissue conditions.

ActiveBoneControl™

A high primary stability in all types of bone can be achieved by the patented combination of bone-specific preparation protocol and bone-condensing thread design.

Friadent® plus surface

The grit-blasted and high temperature-etched Friadent plus microstructure excels by rapid bone formation on the implant surface. This results in early osseointegration and high bone-to-implant contact.





Primary stability and immediate loading

Primary stability is an important factor for successful implant treatment outcomes and is a prerequisite for applying an immediate loading protocol. With the patented combination of a condensing thread design and a bone-specific drill protocol for the Xive implant system, predictable primary stability can be achieved, facilitating immediate loading. In this section, we present results on primary stability and subsequent immediate loading when using the Xive implant system.

Summarized articles:

Comparative analysis study of 702 dental implants subjected to immediate functional loading and immediate nonfunctional loading to traditional healing periods with a follow-up of up to 24 months	10
Primary stability determination by means of insertion torque and RFA in a sample of 4,135 implants	11
Primary stability determination of implants inserted in sinus augmented sites: 1-step versus 2-step procedure	12
Clinical evaluation of immediate implants using different types of bone augmentation materials	13

Comparative analysis study of 702 dental implants subjected to immediate functional loading and immediate nonfunctional loading to traditional healing periods with a follow-up of up to 24 months

Authors: Degidi M, Piattelli A.

Published in: Int J Oral Maxillofac Implants 2005;20(1):99-107.

Aim

The aim of this study was to evaluate implants subjected to immediate functional loading and immediate non-functional loading compared to a conventional loading protocol.

Material and Methods

Patients with different treatment indications were enrolled during a 2-year period between 2001 and 2003. In total, 253 patients were consecutively treated with 702 Xive implants (Dentsply Sirona Implants). Thirty-four patients received an immediate functional loading protocol (group FL, 253 implants), 63 patients were subjected to an immediate non-functional loading (group NF, 135 implants) and 156 patients were treated with a conventional loading protocol (control group, 314 implants). The patients in group FL were completely edentulous while the patients in group NF were partially edentulous, while a mix of indications prevailed in the control group.

Insertion torque value (ITV) and implant stability quotient (ISQ) had to be more than 25 Ncm and >60, respectively, for the implants to be immediately restored.

Implant success criteria was defined as absence of clinical mobility, absence of radiolucency and less than 1.5 mm bone loss 1 year after loading combined with absence of pain, infection and paresthesia.

Radiographic evaluation took place at time of surgery and at 6, 12 and 18 months after surgery (12-month data is presented here).

Results

There were 2 implant failures in the FL group and in the control group, respectively, while the NF group only had one implant failure, resulting in an overall implant survival of 99.3% after up to 2-years. The success rates were 99.2, 99.4 and 99.2, respectively, indicating healthy and clinically stable implants. The prosthesis survival was 100% in both the FL and the control groups and 98.4% in the NF group. Mean marginal bone reduction after 12 months did not differ between the different treatment regimens and were -0.7 mm for both the FL and NF groups and -0.6 mm in the control group.

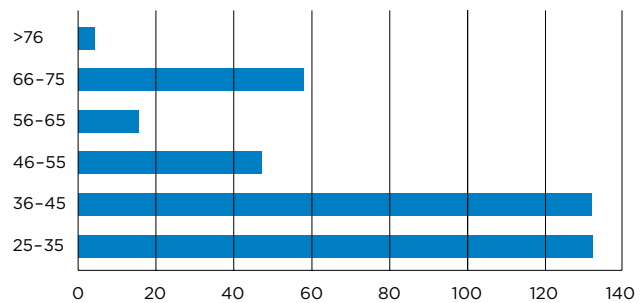


Figure 1. Frequency distribution of number of Xive implants (x-axis) reaching an ITV >25 Ncm (y-axis), i.e. included in the FL or NF groups.

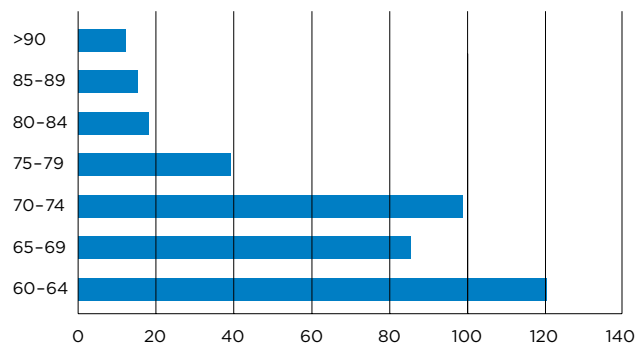


Figure 2. Frequency distribution of number of Xive implants (x-axis) reaching an ISQ >60 (y-axis), i.e. included in the FL or NF groups.

Discussion and Conclusion

This study involved more than 700 Xive implants that were followed for up to 2 years. It was shown that immediate functional loading and immediate non-functional loading have similar good results as the conventional loading regime, provided that a good primary implant stability can be achieved.

Primary stability determination by means of insertion torque and RFA in a sample of 4,135 implants

Authors: Degidi M, Daprile G, Piattelli A.

Published in: Clin Implant Dent Relat Res 2012;14(4):501-07.

Aim

The aim of the study was to evaluate the correlation between primary implant stability, bone density and biomechanical characteristics for Xive implants.

Material and Methods

Patients in need of single or multiple implants and with sufficient bone volume to receive an implant with minimum length of 8 mm and width of 3 mm were eligible for the study. Patients in need of bone augmentation, smoking >20 cigarettes/day, heavy bruxism, high consumers of alcohol, or patients subjected to medication or radiotherapy that could compromise implant treatment were excluded.

In total, 1045 patients rehabilitated with 4135 Xive implants (Dentsply Sirona Implants) were included in the study. All implants were placed by one single surgeon following the instructions given by the manufacturer. The drill sequence was adjusted according to bone density. Before surgery, bone density had been determined by using panoramic as well as peri-apical radiographs.

Primary implant stability was measured by means of peak insertion torque during low speed insertion of the implant, immediately followed by resonance frequency analysis (RFA) measurements (ISQ). The implants were followed for 6 months from installation to record any early implant failures.

Several statistical methods were applied: Kolmogorov-Smirnov to test the data sets distributive normality, Mann-Whitney and Kruskal-Wallis to compare mean values, Spearman test and Eta index to investigate association between different variables and finally chi-squared test for variables in the failed implant group. Level of significance was set to $p < 0.05$.

Results

Six months post-surgery, 28 implants had failed to osseointegrate, rendering a cumulative implant survival rate of 99.3%. Implant failure could not be correlated to either peak insertion torque or RFA measurements.

The mean value of the peak insertion torque measured 34.82 ± 19.36 Ncm where only a weak correlation to length and implant diameter could be shown. Mean RFA value obtained was 71.57 ± 10.63 ISQ. RFA measurements showed a weak correlation to implant diameter, but a relevant correlation to implant length. Implants placed in extraction sockets showed significantly higher peak insertion torque as compared with those placed in healed sites, 36.64 ± 19.47 Ncm and 34.09 ± 19.27 Ncm respectively. The opposite was true for the RFA measurements, with higher ISQ value for healed sites as compared to extraction sockets.

Implant position in the mouth had a correlation to the peak insertion torque value, however the RFA value was not as strongly linked to the position of the implant.

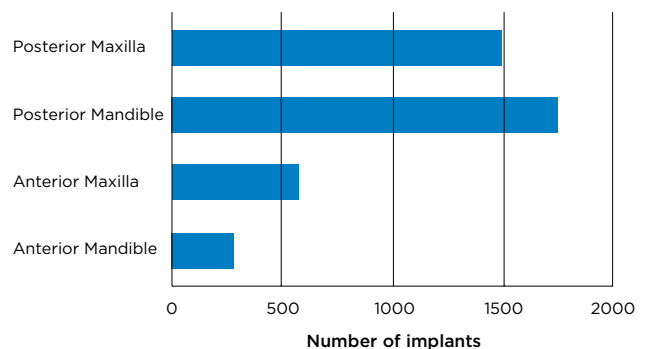


Figure 1. Distribution of implant placement.

Discussion and Conclusion

The results from the study showed that good primary stability, both in healed as well as in extraction sites could be achieved using Xive implants. The RFA measurements were influenced by implant length, whereas peak insertion torque was mostly affected by bone density.

Primary stability determination of implants inserted in sinus augmented sites: 1-step versus 2-step procedure

Authors: Degidi M, Daprile G, Piattelli A.

Published in: Implant Dent 2013;22(5):530-3.

Aim

The purpose of this study was to evaluate the primary stability for Xive implants when placed in the posterior maxilla, either immediately after a sinus lift or 6 months after sinus floor lift.

Material and Methods

Thirty patients, all in need of a unilateral or bilateral sinus lift before implant placement, were included in the study. Group A consisted of 14 patients with a residual bone height of ≥ 4 mm and group B consisted of 16 patients with a residual bone height < 4 mm.

In all cases the grafting material was a combination of 50% Bio-Oss and 50% autogenous bone. Xive implants (Dentsply Sirona Implants) were installed, in group A, a 1-step surgical procedure (simultaneous implant placement with sinus lift) was applied and in group B a 2-step surgical procedure (implant placement 6 months after sinus lift) was applied.

At implant placement peak insertion torque (IT), resonance frequency analysis (RFA) and bone density were recorded as well as implant length and diameter.

Six months after implant placement it was recorded whether an implant was lost or have been removed.

Results

In total 30 patients received 96 Xive implants, 48 implants in group A and group B, respectively.

No statistically significant differences in bone density, diameter or length of implants placed were found between the groups.

The mean peak IT was 23.77 ± 12.63 Ncm in group A and 26.48 ± 20.80 Ncm in group B.

The mean RFA was 65.25 ± 4.45 implant stability quotient (ISQ) in group A and 67.92 ± 10.99 ISQ in group B. None of these IT or RFA differences were statistically significant between the groups.

Six months after implant placement all implants in either group were successfully osseointegrated.

Discussion and Conclusion

The study showed that good primary stability for Xive implants can be achieved when placed in the area treated with a sinus floor lift 6 months earlier as well as when placed immediately after a sinus floor lift.

Diameter and length of implants do not seem to influence primary stability, while the implant design is an important factor to achieve primary implant stability. Xive implants have a crestal design that could condense the periimplant bone during insertion of the implant and obtain a good primary stability.

	No of pat.	No of implants	Surgery	Mean RFA (ISQ)	Mean IT (Ncm)
Group A	14	48	1-stage	65.25 ± 4.45	23.77 ± 12.63
Group B	16	48	2-stage	67.92 ± 10.99	26.48 ± 20.80

Table 1. Primary stability in terms of insertion torque (IT) and resonance frequency analysis (RFA).

Clinical evaluation of immediate implants using different types of bone augmentation materials

Authors: Viswambaran M, Arora V, Tripathi RC. et al.

Published in: Med J Armed Forces India 2014;70(2):154-62.

Aim

This study was conducted to evaluate the stability and healing around implants immediately placed in extraction sockets and augmented with different bone graft materials.

Material and Methods

The patients, all in need of single tooth replacement in the anterior region, had to be generally healthy, non-smoking and having signed a written informed consent in order to be considered for inclusion. Insufficient quality and quantity of the bone at the implant site was an exclusion criterion.

Thirty Xive S plus implants (Dentsply Sirona Implants) with an internal connection and a blasted and high temperature acid etched surface (plus) was placed in 30 patients in conjunction with two different bone graft materials. Demineralized freeze-dried bone allograft (DEMBONE, group A, n=15) and a modified hydroxyapatite (G-BONE, group B, n=15) were used in a random manner to augment the void between the implant and the bony walls of the extraction socket. Cover screws were placed and the wound was closed with sutures. The implants were functionally loaded with porcelain fused to metal crowns after 6 months.

Intra oral radiographical evaluation and soft tissue recordings of Plaque Index (PI), Gingival Index (GI) and sulcus depth, took place at implant placement, 3, 6, 9 and 12 months. Implant stability was assessed at 6, 9 and 12 months through Periotest evaluation.

Results

All implants osseointegrated and were in function at the 12-month follow-up visit. The different bone graft materials did not have an impact on any of the soft tissue variables at 12 months (PI, GI, sulcus depth). Although marginal bone remodeling occurred, bone heights were maintained at the 12 months follow-up in both groups. The graft material did not influence the implant stability measured by Periotest values, which were stable throughout the study period, Table 1.

Periotest	Group A	Group B
6 months	-2.30 (1.19)	-2.20 (1.57)
9 months	-2.27 (1.71)	-3.47 (2.26)
12 months	-2.20 (1.42)	-2.87 (1.41)

Table 1. Mean Periotest values for group A and B, at 6, 9 and 12 months, SD in brackets.

Discussion and Conclusion

Immediate implant placement combined with bone grafting and delayed loading, resulted in stable osseointegration and a 100% implant survival rate after 12 months of follow-up. The type of bone graft material used did not influence Periotest values or any of the soft tissue variables investigated in the current study.



Prosthetic ease and versatility

The Xive implant system offers easy to use and versatile prosthetics, achieved through several specific features; a comprehensive implant and abutment selection, two different implant-abutment connections (internal hex and external square), and a flexible treatment protocol. In this section clinical results on different prosthetic solutions for the Xive implant system are presented.

Summarized articles:

Immediate versus one-stage restoration of small-diameter implants for a single missing maxillary lateral incisor: a 3-year randomized clinical trial	16
A comparison between immediate loading and immediate restoration in cases of partial posterior mandibular edentulism: a 3-year randomized clinical trial	17
Immediate definitive rehabilitation of the edentulous patient using an intraorally welded titanium framework: a 3-year prospective study	18
Overdentures in the edentulous mandible supported by implants and retained by a Dolder bar: a 5-year prospective study	19
Immediate provisionalization of 3.0-mm-diameter implants replacing single missing maxillary and mandibular incisors: 1-year prospective study	20
Soft tissue stability with immediate implants and concave abutments	21

Immediate versus one-stage restoration of small-diameter implants for a single missing maxillary lateral incisor: a 3-year randomized clinical trial

Authors: Degidi M, Nardi D, Piattelli A.

Published in: J Periodontol 2009;80(9):1393-8.

Aim

The aim with the current study was to investigate the peri-implant bone and soft tissue responses around narrow Xive plus implants subjected to either an immediate or a 1-stage restoration protocol to replace missing single maxillary lateral incisors.

Material and Methods

Following a randomization procedure, 30 patients were allocated to the immediate-restoration group and the 1-stage group respectively. All implants placed were 3.0-mm-diameter Xive plus implants (Dentsply Sirona Implants). Only healed sites for replacement of maxillary lateral incisors were considered and patients were excluded from the study if the implants failed to show good primary stability, insertion torque <25Ncm or ISQ <60.

For the immediate-restoration group TempBase abutments (Dentsply Sirona Implants) were re-connected to the implants upon which a temporary crown was relined. The soft tissue was sutured into place after assuring the crown was placed away from occlusal contact in centric and lateral excursions. For the 1-stage group Gingiva former healing abutments (Dentsply Sirona Implants) were screw-retained to the implants around which soft tissue was positioned. The gap was filled by a small removable interim restoration.

Final prosthesis were delivered approximately 6 months post implant insertion.

Parameters investigated during the study were: implant survival, changes in peri-implant bone levels, Jemt's papilla index, probing depth, bleeding on probing and any biological or technical complications. Recall visits were called for after surgery, fitting of temporary restoration/ healing abutment, 6 months, 1, 2 and 3-years after surgery.

Results

A total of 60 implants were placed and all osseointegrated well irrespective of group belonging. No implants failed, rendering a survival rate of 100%.

Complications in 3 patients were recorded, 1 crown fracture, one crown loosening and one case of progressive bone reduction where the patient had a history of periodontal disease. Measure outcomes of clinical and radiologically parameters are depicted in Table 1. Soft tissue levels measured through Jemt's papilla index, showed stable levels over time. There were no statistically significant differences for any of the measured parameters between the 2 different groups.

	Immediate load group	1-stage group
Overall mean bone level change		
Baseline*-3 years	-0.85 mm	-0.75 mm
Insertion torque		
At surgery	45.5 Ncm	41.8 Ncm
ISQ-values		
At surgery	69.5	72.9
At 6 months	77.1	78.6
Probing depth		
At 6 months	1.73	1.97
At 3 years	1.91	2.27
Bleeding on probing		
At 6 months	19.4	21.3
At 3 years	17.9	20.3

*Baseline was set to fitting of the temporary restoration/ healing abutment.

Table 1. Bone level change, insertion torque, ISQ-value, probing depths and bleeding on probing.

Discussion and Conclusion

Narrow-diameter Xive plus implants were shown to be a predictable treatment for the rehabilitation of missing maxillary lateral incisors when applying either an immediate loading protocol or a 1-stage restoration procedure.

A comparison between immediate loading and immediate restoration in cases of partial posterior mandibular edentulism: a 3-year randomized clinical trial

Author: Degidi M, Nardi D, Piattelli A., et al.

Published in: Clin Oral Implants Res 2010;21(7):682-87.

Aim

The aim of this 3-year randomized controlled study was to compare survival rate, bone loss and soft healing pattern at immediately loaded implants with implants provisionalized but not in occlusion.

Material and Methods

This single center randomized study included patients that had received two Xive plus implants (Dentsply Sirona Implants) in the posterior mandible with no exclusion criteria applied. Exclusion criteria were related to acceptance of surgery and to implant stability such as insertion torque (ITV) >25 Ncm and implant stability quotient (ISQ) >60.

The implants were placed 0.5 mm above the alveolar crest in healed ridges and splinted by an intraoral welding technique. Thereafter flaps were sutured and treatment allocation occurred. Test implants were immediately provisionalized with temporary bridges made in full occlusion while control implants had their immediate temporary bridges reduced to avoid centric and lateral occlusion. Both test and control implants were restored with permanent full occluding restorations 6 months after implant placement.

Implant survival was assessed throughout the study period. Marginal bone levels were assessed at day of surgery, at 6 months (final prosthesis delivery) and at 1, 2 and 3 years after surgery. The probing pocket depth (PPD) and bleeding on probing (BoP) were assessed after 20 weeks by standardized probing (0.15 N) at mesial, distal and buccal sites.

Results

Fifty patients were included and they received in total 100 Xive plus implants in the mandibular molar region. Two implants did not osseointegrate and were removed at 5 and 7 weeks after surgery, resulting in a 98% survival rate. Implant stability is presented in table

1 and probing pocket depth and presence of bleeding is presented in table 2. There were no differences between the groups related to these parameters. The mean marginal bone loss is presented in table 3 and no significant differences between the groups at any time point were found.

Mean	ISQ	ITV
Test group	65.9 (SD 7.2)	30.5 (SD 9.1)
Control group	66.1 (SD 8.6)	28.7 (SD 5.2)

Table 1. ISQ and ITV (Ncm) at implant placement.

Mean	PPD	BoP
Test group	1.60 (SD 0.2)	19.1
Control group	1.61 (SD 0.3)	18.1

Table 2. PPD (mm) and BoP (%) after 20 weeks.

Mean	6 months	3 years
Test group	0.69 mm	0.95 mm
Control group	0.71 mm	0.99 mm

Table 3. Marginal bone level change.

Discussion and Conclusion

The results of this study showed that there were no significant differences in implant survival rates and hard and soft tissue reactions between implants immediately temporized to full functional load and implants immediately temporized but not in full occlusion. Within a 3-year period, immediate loading of splinted two-implant supported prostheses in the posterior mandible seems not to compromise the osseointegration processes.

Immediate definitive rehabilitation of the edentulous patient using an intraorally welded titanium framework: a 3-year prospective study

Authors: Degidi M, Nardi D, Piattelli A.

Published in: Quintessence Int 2010;41(8):651-9.

Aim

The focus of this prospective study was to evaluate whether intraoral welding is a viable concept for immediate rehabilitation of the edentulous patient.

Material and Methods

All 60 included patients were completely edentulous in the mandible or in the maxilla. Following full-thickness flap surgery, they all received 4 Xive plus implants (Dentsply Sirona Implants) placed in healed ridges using a surgical template.

The insertion torque and the implant stability were registered and patients were excluded from the study if any of the implants did not achieve good primary stability, which was defined as insertion torque <25 Ncm and ISQ <60.

If sufficient primary stability was reached, definitive abutments were connected to the implants through screw retention and then a titanium cylinder was connected to each abutment after which a 2-mm-diameter titanium bar was intraorally welded to the first distal abutment on the left. Using pliers, the bar was shaped to achieve passive contact with the abutment situated next to the one just welded. This procedure was repeated for all abutments. When complete contact between the curved bar and the abutments were ensured they were welded together using an intraoral welding unit.

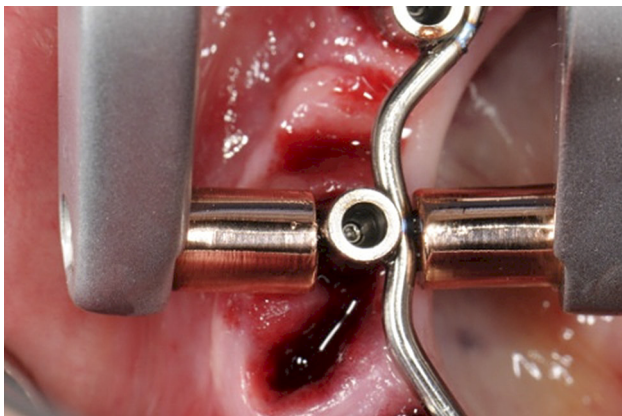

Figure 1. The curved bar and the abutments were welded together using an intraoral welding unit.

The intraoral welding process does not cause any discomfort to the patient since no heat is transferred to the surrounding tissues or to the peri-implant area.

By using the Sheffield 1 screw test the passive fit of the framework was confirmed. The soft tissue was repositioned and sutured around the abutments and the prosthetic framework was relined with acrylic and screw retained the same day, applying 20 Ncm.

Patients were instructed in oral hygiene and were recommended a soft diet for 4 weeks after surgery.

Clinical parameters registered were; prosthetic success, implant survival, changes in peri-implant bone levels as well as biological and technical complications.

Results

In total, 60 patients received 324 Xive plus implants supporting an intraorally welded titanium framework facilitating immediate loading.

The overall implant survival rate was 99.1% after 6 months. From implant placement to the 3-year visit the mean marginal bone level change was 0.97 mm in the mandible and 1.02 mm in the maxilla. Within 8 weeks after surgery three patients reported on swelling, discomfort and pain due to mobile implants. Each patient had one implant removed and the restorations re-adapted the same day.

Only minor prosthetic complications occurred in two patients, small acrylic fractures that were easily repaired, resulting in a prosthetic success rate of 96.7 % after 3 years.

Discussion and Conclusion

From this 3-year prospective study it was concluded that it is possible to successfully rehabilitate edentulous patients with immediate loading of Xive plus implants when using an intraorally welded prosthetic framework, without compromising osseointegration.

Overdentures in the edentulous mandible supported by implants and retained by a Dolder bar: a 5-year prospective study

Authors: Heschl A, Payer M, Clar V, et al.

Published in: Clin Implant Dent Relat Res 2013;15(4):589-99.

Aim

The purpose of this investigation was to evaluate the clinical performance of Xive S plus implants when placed in the edentulous mandible followed by restoration with bar structures and overdentures.

Material and Methods

Thirty-nine patients were rehabilitated with a total of 156 Xive S plus implants (Dentsply Sirona Implants) in the interforaminal region of the mandible.

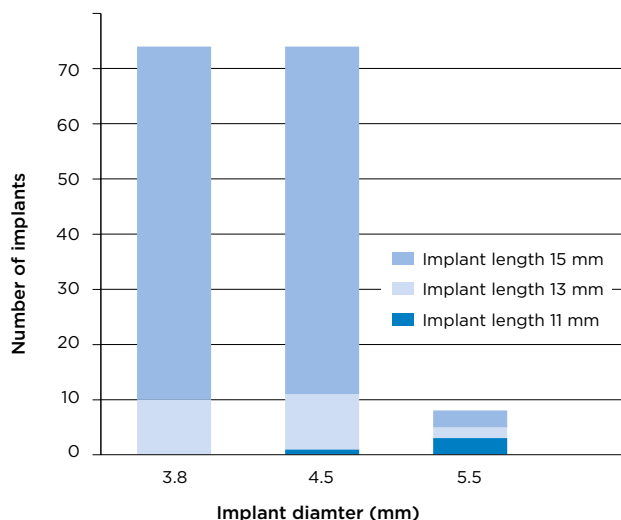


Figure 1. Distribution of implant lengths and diameters used in the study.

Following 3 months of submerged healing the 4 interforaminal implants were exposed and splinted using a Dolder bar connected to MP abutments (Dentsply Sirona Implants). The complete overdentures were attached via 3 retention clips cured into the denture.

Intraoral radiographs were taken at implant placement (baseline) and yearly thereafter for up to 5 years to follow periimplant bone level changes. Clinical parameters such as; plaque occurrence, calculus,

bleeding on probing, mucosal index value and probing depths were recorded at yearly re-call visits. Moreover, primary implant stability, periostest values, survival rates and prosthetic complications were also recorded.

Results

33 patients attended the 5 year follow-up. Overall mean bone loss during the 5 year study period measured 1.1 mm. No statistical difference in bone level changes could be found between posteriorly and anteriorly placed implants.

Mean values for plaque occurrence, calculus, bleeding on probing and mucosal index all remained low throughout the investigational period, depicted in Table 1. No correlation between periimplant soft tissue health and crestal bone level changes could be established. The median Periotest values were -5 at all recall visits throughout the study. Primary stability measured >30 Ncm for 139 implants. Implant survival rate at the end of the observational period was 98.6% and prosthetic survival was 100%.

Time	Plaque index	Calculus index	Gingival index	Bleeding index
1 year	0.4	0.4	0.5	0.9
2 years	0.4	0.5	0.5	1.1
3 years	0.5	0.5	0.5	0.3
4 years	0.5	0.5	0.6	1.3
5 years	0.5	0.5	0.7	1.3

Table 1. Mean plaque index, calculus index, gingival index and bleeding index changes over time.

Discussion and Conclusion

During the 5 year observational period, Xive S plus implants, in combination with Dolder bars and overdentures, showed low rates of prosthetic complications, high survival rates and stable periimplant tissue levels when placed in the edentulous mandible.

Immediate provisionalization of 3.0-mm-diameter implants replacing single missing maxillary and mandibular incisors: 1-year prospective study

Authors: Oyama K, Kan JY, Rungcharassaeng K, et al.

Published in: Int J Oral Maxillofac Implants 2012;27(1):173-180.

Aim

This prospective study aimed to evaluate the 1-year clinical outcome of narrow Xive S plus implants (Ø3.0 mm) when immediately restored with single crowns.

Material and Methods

Thirteen patients in need of single tooth restorations in the maxillary or mandibular incisor region were included. Seventeen narrow Xive S plus implants (Dentsply Sirona Implants) were placed in healed alveolar ridges and restored at the day of surgery with EstheticBase abutments (Dentsply Sirona Implants) and a provisional crown, clearing all centric and eccentric contact points. Implants were placed with a minimum torque of 25 Ncm. Permanent customized abutments and crowns were connected 3 months following implant insertion.

Clinical and radiographic evaluations were performed at implant surgery and at 3, 6 and 12 months. Implant stability was measured with a Periotest device and papilla index score was evaluated according to the Jemt¹ papilla index.

Jemt¹ papilla index:

- 0= no papilla present
- 1= less than half of the papilla is present
- 2= half or more of the height of the papilla is present
- 3= the papillae fill up the entire proximal space and are in good harmony with the adjacent papillae
- 4= the papillae are hyperplastic and covers too much of the implant restoration and/or adjacent tooth

Time	Mean	Range
Implant placement	-1.59 ± 1.70	-4 to 2
Definitive impression (3 months)	-2.65 ± 1.77	-7 to 0

Table 1. Periotest values over time.

Results

Nine implants were placed in the maxilla and 8 implants were placed in the mandible. Implants were placed in type 2 bone (n=11), type 3 bone (n=5), and type 4 bone (n=1)² After 1 year in function, all 17 implants were successfully osseointegrated. Cumulative implant success according to Smith and Zarb³ was 100%. Mean marginal bone level change between implant placement and 1-year follow-up was -0.35 ± 0.35 mm.

Clinical variables such as modified bleeding and plaque indexes remained unchanged and at a low level throughout the whole study.

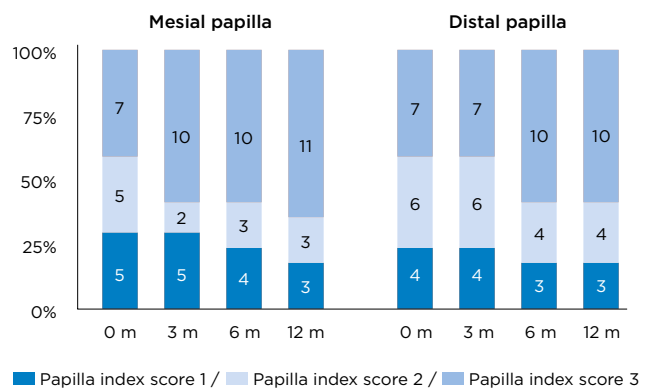


Figure 1. Papilla index score up to 12 months after implant placement and provisionalization. Papilla index score according to Jemt papilla index¹ where no sites had papilla index score 0 or 4. m = months.

Periotest values were significantly improved over time, as shown in Table 1.

All sites had papilla index score 1 to 3 according to Jemt papilla index¹ and a significant gain in papilla height was detected over time (Figure 1).

Discussion and Conclusion

Immediate provisionalization with narrow Xive S plus implants in indicated areas, exhibited a good clinical outcome with maintained marginal bone and papilla following 1 year in function.

References:

1. Jemt T. Regeneration of gingival papillae after single-implant treatment. Int J Periodontics Restorative Dent 1997;17:327-333.
2. Lekholm U, Zarb GA. Patient selection and preparation. In: Branemark PI, Zarb GA, Albrektsson T (eds). Tissue-Integrated Prostheses: Osseointegration in Clinical Dentistry. Chicago: Quintessence, 1985:199-210.
3. Smith DE, Zarb GA. Criteria for success of osseointegrated endosseous implants. J Prosthet Dent 1989;62:567-572.

Soft tissue stability with immediate implants and concave abutments

Authors: Redemagni M, Cremonesi S, Garlini G. et al.

Published in: Eur J Esthet Dent 2009;4(4):328-37.


Aim

The aim of this study was to observe the alterations of the peri-implant tissues after immediate implant installation of single implants restored with abutments having a concave design.

Material and Methods

Patients with a single implant placed between two healthy neighboring teeth in the esthetic zone were included in this retrospective study. Complete patient records of the treatment, such as radiographs and photographs had to be available and in good quality for patient inclusion.

Following gentle tooth extraction, a Xive implant (Dentsply Sirona Implants) was immediately placed. The implant was positioned in level with the buccal bone margin and 2 to 3 mm apically to the free gingival margin. A provisional crown was prepared onto the TempBase abutment (Dentsply Sirona Implants) and great care was taken to achieve a concave transmucosal design and a crown free from occluding contacts. During the finalization of the temporary crown a connective tissue graft was harvested from the palate and placed in a buccal pouch (created with a Prichard instrument). The graft was sutured and the temporary crown was screwed in place. Six to 12 months later a custom made abutment was placed supporting a cement-retained definitive crown.



Radiographic evaluation of the bone-to implant contact (i.e. bone level in relation to the implant shoulder) was performed. On photographs, a reference line was drawn between neighboring incisal edges (or premolar cusps) and perpendicular to this line the gingival zenith and height of papillae were measured at time for baseline (implant placement) and at the last follow-up.

Results

Twenty-eight patients were included and followed between 6 to 50 months, with an average follow-up time of 20 months. No clinical or technical complications occurred and all implants and crowns were in function at the last follow-up. Minor physiological bone remodeling was observed with mean bone level changes of -0.28 mm and -0.24 mm mesial and distal to the implant, respectively. Changes in mesial and distal papillae were -0.21 mm and -0.02 mm, respectively. The gingival zenith remained unchanged.

Discussion and Conclusion

This short term study with 28 patients reported stable marginal bone levels and maintained buccal and interproximal soft tissues. The use of concave abutments allowed for a wider soft tissue contour which was aided by the soft tissue graft.



Long-term clinical results

The Xive implant system has been in clinical use for more than a decade. Long-term clinical documentation (i.e. ≥ 5 years) is one of the most important tools when showing evidence for the Xive implant system being efficient, reliable and safe. In this section, long-term results with up to 10 years of clinical follow-up are presented.

Summarized articles:

A six-year follow-up of full-arch immediate restorations fabricated with an intraoral welding technique	24
Immediate rehabilitation of the edentulous mandible with screw type implants: results after up to 10 years of clinical function	25
Bone level variation after vertical ridge augmentation: Resorbable barriers versus titanium-reinforced barriers. A 6-year double-blind randomized clinical trial	26
Immediate provisional restoration of screw-type implants in the posterior mandible: results after 5 years of clinical function	27

A six-year follow-up of full-arch immediate restorations fabricated with an intraoral welding technique

Authors: Degidi M, Nardi D, Piattelli A.

Published in: Implant Dent 2013;22(3):224-31.

Aim

The purpose with this prospective study was to evaluate the 6-year clinical outcome of Xive plus implants subjected to immediate loading when restored with a full-arch prosthesis constructed through an intraoral welding technique.

Material and Methods

Patients suffering from complete edentulism in either jaw were considered eligible for the study. All patients were rehabilitated with Xive plus implants (Dentsply Sirona Implants). Insertion torque and implant stability quotient (ISQ) were monitored during implant insertion and if the insertion torque or the ISQ value did not reach 25 Ncm or 60 respectively, the patients were excluded from the study.

For implant placement, which took place in healed sites only, a full-thickness flap was elevated whereupon the implants were placed in a way to position the polished collar 0.4 mm above the alveolar crest. To ensure parallelism between all implants, abutments with an external circular and conical connection were screw retained on to the implants. A welding abutment was then attached to the already connected abutments to ensure that the framework could be removed after welding. A titanium bar was welded onto these 2-part abutments utilizing the intraoral welding technique. The structure was removed and strengthened with extraorally welded titanium bars then sandblasted and opaqued. Soft tissue was repositioned and the prosthesis was filled with acrylic and screw retained on the same day, applying full occlusal load.

Implant survival, periimplant bone remodeling and any biological or technical complications were recorded during the 6 year study period. Patients were rescheduled for follow-up visits 6 months after surgery and thereafter on a yearly basis.

Results

In total 52 patients were rehabilitated with 256 implants. Following 6 years 3 implants failed to osseointegrate and 42 implants were lost to follow-up. The average bone remodeling for mandibular and maxillary placed implants were -1.29 mm and -1.39 mm respectively.

Reported biological and technical complications are specified in Table 1. Seven implants were diagnosed with periimplantitis. For these patients the prosthesis was removed, full-thickness flap was elevated to clean the implant surface and bony defect and the problems were resolved.

Complication type	No. of reported complications
Periimplantitis	7
Mucositis	25
Sensory disturbance	1
Moderate chewing difficulties	2
Fracture of the acrylic resin super-structure	5
Complete fracture of the resin portion	1
Fracture of fixing screws	1
Need of relining procedure	9

Table 1. Biological and technical complications.

Discussion and Conclusion

This study was able to show that the intraoral welding technique in combination with immediately loaded Xive plus implants is a viable treatment concept, both for the mandible and the maxilla following 6 years in function.

Immediate rehabilitation of the edentulous mandible with screw type implants: results after up to 10 years of clinical function

Author: Heschl A, Payer M, Platzer S, et al.

Published in: Clin Oral Implants Res 2012;23(10):1217-23.

Aim

The focus of this prospective study was to evaluate 10-year survival and success rates of immediately loaded Xive implants in the edentulous mandible.

Material and Methods

Between 2000 and 2004, 30 patients received a total of 120 Xive implants (Dentsply Sirona Implants) that were inserted in the interforaminal region in healed ridges.

4 implants, either Xive S plus or Xive TG, were placed supracrestally in all patients. Healing abutments (Gingiva Formers, Dentsply Sirona Implants) were inserted at time of surgery and within a week all implants were loaded by using a gold Dolder bar and one retention clip, which was cured into the hybrid prosthesis.

Three months later the distal extensions were welded to the bars and 3 retention clips were cured into the existing overdentures. Five patients requested fixed screw-retained prostheses instead of overdentures.

Intraoral digital radiographs were used to evaluate the crestal bone loss, using the time of final superstructure connection as baseline compared to the yearly follow-up visits. The bone levels were evaluated by measuring the distance from the implant shoulder to the crestal bone margin.

Other clinical parameters registered at these follow-ups were; occurrence of plaque and calculus, bleeding on probing, pocket probing depth and Periotest values. The peri-implant soft tissue was assessed after the bars were removed for a thorough cleaning.

Results

Following 10 years in function the overall implant survival rate was 98.3%. Extensive bone loss occurred around 4 implants after 2 years in function, rendering an implant success rate of 95%.

From time of final superstructure delivery and up to the 8-year follow-up a mean bone level change of 1.80 mm (SD \pm 0.65) was recorded. From 8 years and onwards bone levels were stable (Table 1).

Time (years)	Bone levels (mm)	
	mean	SD
Baseline	0.51	0.29
1	1.26	0.51
3	1.53	0.63
5	1.73	0.74
10	1.78	0.38

Table 1. Mean marginal bone levels measured from the implant-shoulder to the crestal bone margin.

Between follow-up visits 1 and 8 years, the median Periotest values ranged from -4 to -4.5, with an increase of up to -6 the last 2 years.

The vast majority of patients showed good soft tissue health confirmed by low mean values of plaque, calculus, bleeding on probing and mucosal index throughout the follow-up period. The mean probing depth increased with 1.39 mm during the 10-year observational period.

Discussion and Conclusion

From the results of this 10-year study it was concluded that Xive implants placed in the interforaminal region, splinted by a Dolder bar and immediately loaded were a predictable treatment option for selected patients.

Bone level variation after vertical ridge augmentation: Resorbable barriers versus titanium-reinforced barriers. A 6-year double-blind randomized clinical trial

Authors: Merli M, Moscatelli M, Mariotti G, et al.

Published in: Int J Oral Maxillofac Implants 2014;29(4):905-13.

Aim

This double-blinded randomized controlled study aimed to compare bone level changes around Xive S plus implants placed in partially edentulous patients when applying vertical ridge augmentation in combination with resorbable or nonresorbable membranes.

Material and Methods

In total, 22 partially edentulous patients in need of vertical bone augmentation for the planned implant sites were found eligible for the study. For bone augmentation the autograft was mostly harvested from areas adjacent to the implant site facilitated by a bone trap.

Patients were randomized either to receive treatment with a nonresorbable titanium-reinforced expanded polytetrafluoroethylene barrier, Gore Regenerative Membrane (control) or a resorbable collagen barrier supported by an osteosynthesis plate, Bio-Gide (test). Xive S plus implants (Dentsply Sirona Implants) were placed in conjunction with augmentation in all patients with a 2-stage surgical approach where abutment connection took place 5 months following implant placement. The nonresorbable and the osteosynthesis plates were removed and 2 weeks later the provisional single and partial screw-retained prostheses were connected. Definitive metal-ceramic prostheses were delivered after 2-3 months.

Intraoral radiographs were collected at abutment connection, loading and then at 1, 3 and 6 years after loading. In addition periodontal and peri-implant supportive therapy was conducted every 3 months during the first year and then every 6 months during the following years.

Results

In total 97 Xive S plus implants were placed, 42 in the test group and 55 in the control group. However, in case of multiple implants only the implant with the higher defect was selected, leaving 10 control implants and 11 test implants included in the study. One patient was lost to follow-up. All implants remained in function during the 6 year study period, rendering a survival rate of 100% for both groups. Bone levels are depicted in table 1. Total bone loss from loading to the 6 year follow-up visit was 0.58 mm for the test group and 0.49 mm for the control group, where no statistical difference was found between groups.

No biological or prosthetical complications occurred after loading.

Time from loading (years)	Marginal bone level (mm)	
	Resorbable membrane (test)	Nonresorbable membrane (control)
0	0.75	0.54
3	1.30	1.07
6	1.33	1.00

Figure 1. Bone levels over time for patients treated with resorbable (test) and nonresorbable (control) membranes.

Discussion and Conclusion

No difference between resorbable and nonresorbable barriers placed in conjunction with implants for vertical ridge augmentation was observed in this long-term randomized clinical trial. Interproximal vertically regenerated bone was well maintained around Xive S plus implants after 6 years of functional loading.

Immediate provisional restoration of screw-type implants in the posterior mandible: results after 5 years of clinical function

Authors: Payer M, Heschl A, Wimmer G. et al.

Published in: Clin Oral Implants Res 2010;21(8):815-21.

Aim

The aim of this prospective study was to evaluate the long-term clinical outcome of Xive implants when placed in the posterior mandible and immediately provisionalized.

Material and Methods

Patients eligible for the study had to have sufficient amount of horizontal and vertical bone to harbour a 11x3.8 mm Xive implant (Dentsply Sirona Implants), >32 Ncm insertion torque and a written consent accepting clinical and radiographic analysis and performing maintenance visits. Patients with parafunctions, periodontal disease or being smokers were excluded.

The implants were placed in healed sites (6 months postextraction) with the platform above the bony crest. A TempBase abutment supported the immediate provisional restorations. After 6 months a final metal-ceramic crown/bridge was cemented on EstheticBase abutments (Dentsply Sirona Implants).

Patients were examined at baseline (i.e. cementation of the final restoration) and thereafter scheduled for annually follow-up visits.

Results

Twenty-four patients received 19 single molar crowns and 21 implants supported 2-or 3-unit fixed partial prostheses. Thirty-eight implants were placed in the mandible molar area while 2 were placed in the second premolar position. Two implants failed during the first year resulting in a cumulative survival rate of 95% after 5-years, see Table 1.

Postoperative radiographic examination showed a mean bone level of 0.33 mm below the implant shoulder at implant placement (all implants were placed supraestally). A significant bone reduction

occurred after 1-year, measuring an average bone level at 1.06 mm. No further bone reduction took place at either mesial and distal sites rendering an average bone level of 1.21 mm after 5 years. A subanalysis during the first year showed that single implants had significantly less bone reduction compared to the implants supporting partial bridges. Clinical examination during the healing phase showed few cases of minor swelling. Complications were restricted to mucositis and loosening of provisionals. At 8 weeks, one patient lost periodontal attachment at a neighbouring tooth and the peri-implant tissue was inflamed. This incident was successfully treated. Thereafter, oral hygiene and soft tissue status were excellent throughout the whole study period.

Time (years)	Implants (at risk)	Failed	Cumulative survival rate (%)
0-1	40	2	95
1-2	38	0	95
2-3	38	0	95
3-4	38	0	95
4-5	36	0	95

Table 1. Life table analysis.

Discussion and Conclusion

Patients were carefully selected to receive immediately provisionalisation of implants placed in the posterior mandible supporting single crowns or small partial bridges. The long-term implant survival rate from the current study is comparable with survival rates where submerged healing and conventional loading protocol are applied.

References

- Degidi M, Daprile G, Piattelli A.
Primary stability determination by means of insertion torque and RFA
in a sample of 4,135 implants.
Clin Implant Dent Relat Res 2012;14(4):501-07 11
- Degidi M, Daprile G, Piattelli A.
Primary stability determination of implants inserted in sinus augmented sites:
1-step versus 2-step procedure.
Implant Dent 2013;22(5):530-312
- Degidi M, Nardi D, Piattelli A.
A comparison between immediate loading and immediate restoration in cases
of partial posterior mandibular edentulism: a 3-year randomized clinical trial.
Clin Oral Implants Res 2010;21(7):682-8717
- Degidi M, Nardi D, Piattelli A.
A six-year follow-up of full-arch immediate restorations fabricated
with an intraoral welding technique.
Implant Dent 2013;22(3):224-31 24
- Degidi M, Nardi D, Piattelli A.
Immediate definitive rehabilitation of the edentulous patient using
an intraorally welded titanium framework: a 3-year prospective study.
Quintessence Int 2010;41(8):651-9 18
- Degidi M, Nardi D, Piattelli A.
Immediate versus one-stage restoration of small-diameter implants
for a single missing maxillary lateral incisor: a 3-year randomized clinical trial.
J Periodontol 2009;80(9):1393-8 16
- Degidi M, Piattelli A.
Comparative analysis study of 702 dental implants subjected to immediate
functional loading and immediate nonfunctional loading to traditional
healing periods with a follow-up of up to 24 months.
Int J Oral Maxillofac Implants 2005;20(1):99-107 10
- Heschl A, Payer M, Clar V, Stopper M, Wegscheider W, Lorenzoni M.
Overdentures in the edentulous mandible supported by implants and retained
by a dolder bar: a 5-year prospective study.
Clin Implant Dent Relat Res 2013;15(4):589-99 19
- Heschl A, Payer M, Platzer S, Wegscheider W, Pertl C, Lorenzoni M.
Immediate rehabilitation of the edentulous mandible with screw type implants:
results after up to 10 years of clinical function.
Clin Oral Implants Res 2012;23(10):1217-23 25

Merli M, Moscatelli M, Mariotti G, Rotundo R, Bernardelli F, Nieri M. Bone level variation after vertical ridge augmentation: resorbable barriers versus titanium-reinforced barriers. A 6-year double-blind randomized clinical trial. Int J Oral Maxillofac Implants 2014;29(4):905-13	26
Oyama K, Kan JY, Rungcharassaeng K, Lozada J. Immediate provisionalization of 3.0-mm-diameter implants replacing single missing maxillary and mandibular incisors: 1-year prospective study. Int J Oral Maxillofac Implants 2012;27(1):173-80	20
Payer M, Heschl A, Wimmer G, Wegscheider W, Kirmeier R, Lorenzoni M. Immediate provisional restoration of screw-type implants in the posterior mandible: results after 5 years of clinical function. Clin Oral Implants Res 2010;21(8):815-21	27
Redemagni M, Cremonesi S, Garlini G, Maiorana C. Soft tissue stability with immediate implants and concave abutments. Eur J Esthet Dent 2009;4(4):328-37	21
Viswambaran M, Arora V, Tripathi RC, Dhiman RK. Clinical evaluation of immediate implants using different types of bone augmentation materials. Med J Armed Forces India 2014;70(2):154-62	13

Notes

Checklist for critical reading of clinical documentation and scientific articles

Reading scientific articles and clinical documentation is essentially about being able to judge how reliable the results are and what they mean for you in your clinical work. In order for a scientific article to be deemed credible, certain data must be present. Here is a list of important and necessary information to look for:

Purpose of the study

Why was the study performed? The purpose should be compared with the conclusion.

Type of study

Is it a prospective or retrospective study? Generally, prospective studies are better, since the criteria are set before the patients are treated.

Number of clinics involved

How many clinics are involved? More than one clinic should be involved in the study, in order to judge the possibility of repeated results.

Number of patients

How many patients are included in the study?

Inclusion and exclusion criteria

What are the criteria for a patient to be included in or excluded from the study?

Number of implants for upper and lower jaws respectively

The number of implants should always be listed separately for upper and lower jaws, including failure statistics, as the treatment prognosis is different in each jaw. An additional advantage is if you can see the difference between anterior and posterior treatment.

Follow-up

How many implants have been followed for how long? When did the follow-up start; at installation or at loading?

Indications

Which indications are covered in the study; single, partial or full bridge? If it is a full bridge, is it fixed prosthesis or overdenture?

Loading

When were the implants loaded (immediate, early or conventional loading)?

Implants lost

A study should include both the number of implants and number of patients not accounted for during the entire follow-up period. It should also include the reasons for drop-outs.

Success criteria

What is a successful result according to the authors? It is important that the success criteria are clearly described.

Other important parameters

How were the results verified? Was x-ray used when determining bone levels? How were bone levels measured? Was the bridge removed to control implant stability?

Statistical analysis of success and failure rates

A study should include statistical facts and figures to reveal how many implants were actually followed up and for how long. It should also include a "worst-case" analysis, meaning a calculated failure rate assuming that all drop-outs were lost implants.

Complications

If there are complications or drop-outs, they should be clearly described.

Conclusion

The conclusion should be compared with the purpose of the study. Was it fulfilled? What does the study actually tell you? How does the result affect your daily clinical work?

About Dentsply Sirona Implants

Dentsply Sirona Implants offers comprehensive solutions for all phases of implant therapy, including Ankylos®, Astra Tech Implant System® and Xive® implant lines, digital technologies, such as Atlantis® patient-specific solutions and Simplant® guided surgery, Symbios® regenerative solutions, and professional and business development programs, such as STEPPS™. Dentsply Sirona Implants creates value for dental professionals and allows for predictable and lasting implant treatment outcomes, resulting in enhanced quality of life for patients.

About Dentsply Sirona

Dentsply Sirona is the world's largest manufacturer of professional dental products and technologies, with a 130-year history of innovation and service to the dental industry and patients worldwide. Dentsply Sirona develops, manufactures, and markets a comprehensive solutions offering including dental and oral health products as well as other consumable medical devices under a strong portfolio of world class brands. As The Dental Solutions Company™, Dentsply Sirona's products provide innovative, high-quality and effective solutions to advance patient care and deliver better, safer and faster dentistry. Dentsply Sirona's global headquarters is located in York, Pennsylvania, and the international headquarters is based in Salzburg, Austria. The company's shares are listed in the United States on NASDAQ under the symbol XRAY.

Visit www.dentsplysirona.com for more information about Dentsply Sirona and its products.