

Ankylos implant placement and two CELTRA DUO crowns – Teeth 12 and 22, in 180 minutes

Case Description

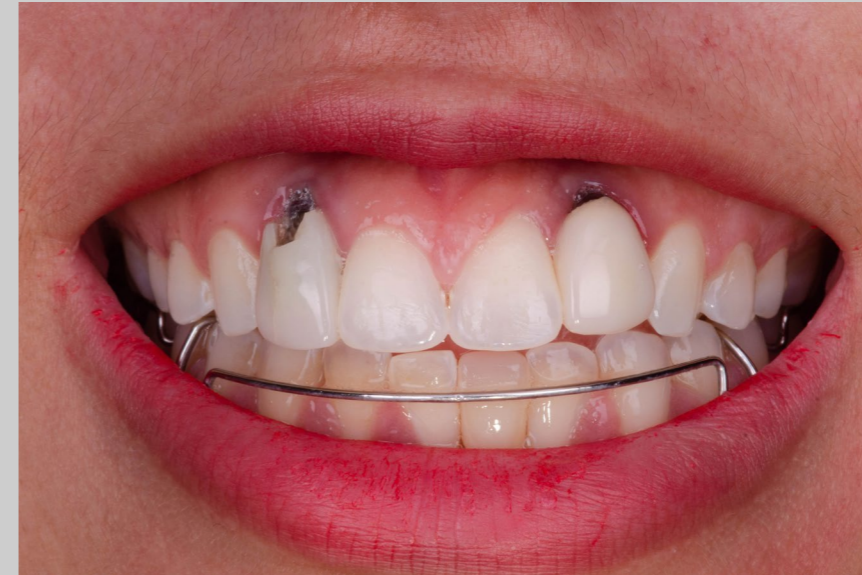A 22-year-old female patient came to my practice. The medical history revealed that teeth 12 and 22 were missing due to dental agenesis and had been replaced by implants. This solution did not please the patient at all. She hid her smile and felt inhibited around company. She wished to be able to laugh again with confidence. Restorations in the anterior region pose a particular challenge, especially from an esthetic point of view. In this case, the absence of teeth 12 and 22 and the bone loss caused by the first implants, which had not been optimally placed, also had to be taken into account. After their removal, augmentation with a bone graft and a collagen membrane (Bio-Oss, Bio Gide, Geistlich) was necessary. In a second surgical step six months later, two Ankylos implants (A9) were inserted and a soft tissue graft was placed. The patient then received chairside fabricated temporaries. After a further three months, I provided the patient with a final CEREC restoration. I took a digital impression with CEREC Primescan in conjunction with the TiBase Ankylos CEREC GH2, including scan post and scan body, and then designed two crowns in the CEREC software which fit perfectly into the patient's dentition. Both crowns were then ground from a Celtra Duo HT block in shade A1 using CEREC Primemill. After staining and glazing in the CEREC SpeedFire, the restorations were cemented onto a custom zirconium abutment (InCoris Meso with TiBase), milled in the CEREC Primemill and sintered in the CEREC SpeedFire. These steps were carried out in a single visit, which lasted a total of approximately 180 minutes.

Discussion

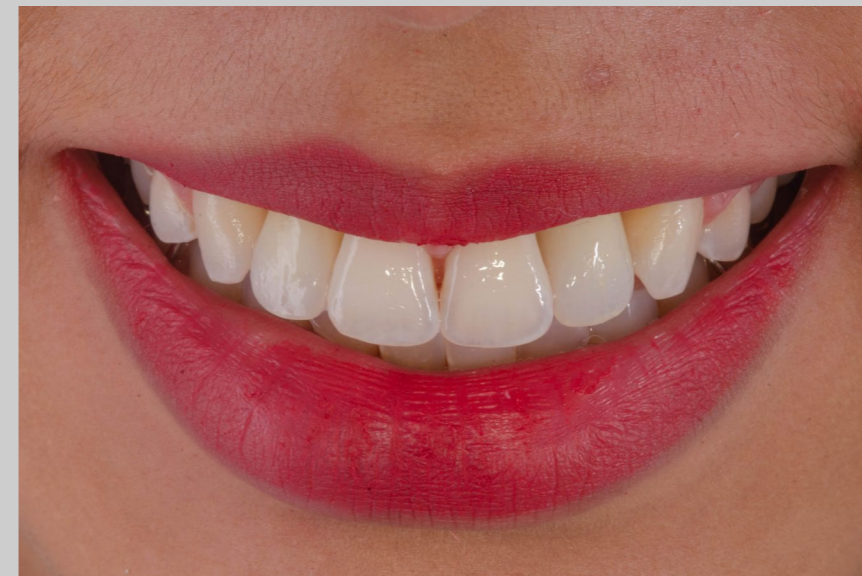For an adequate result from a functional and esthetic point of view, the removal of both previous implants was unavoidable. The treatment options were an orthodontic gap closure, a restoration with bridges or two single-tooth restorations with implants and chairside fabricated crowns, the latter of which the patient preferred. In the end, she was able to receive two completely new restorations in only three visits and was very happy with her new smile.



Dr. Fernando Peixoto Soares
São Paulo, Brazil

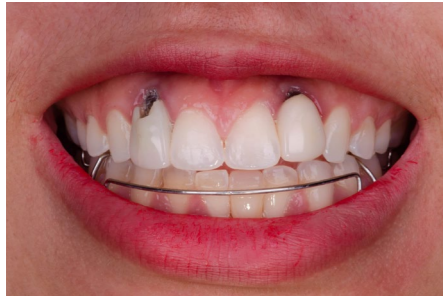

Before:
Initial situation

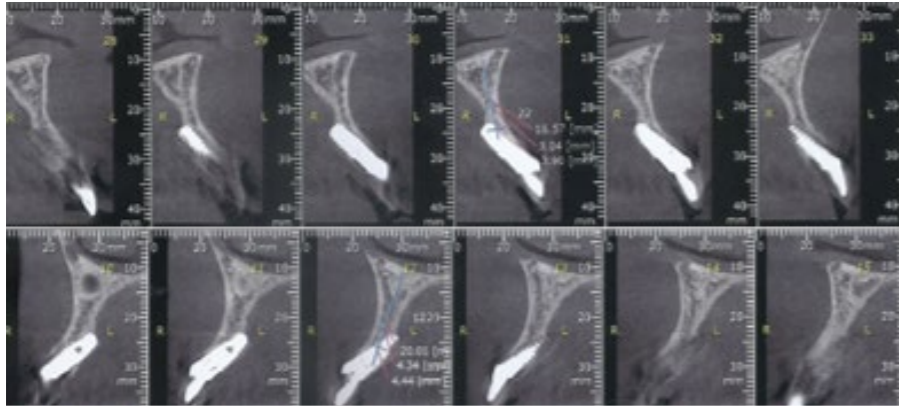


After:
Final smile

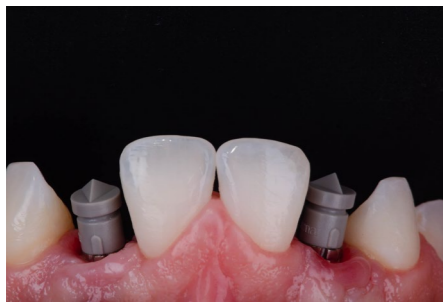Clinical Images



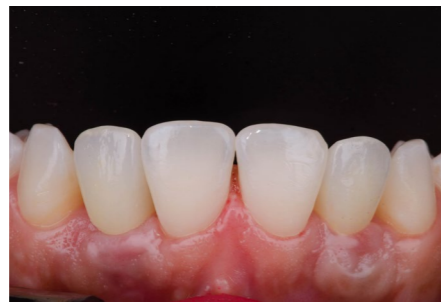Initial situation



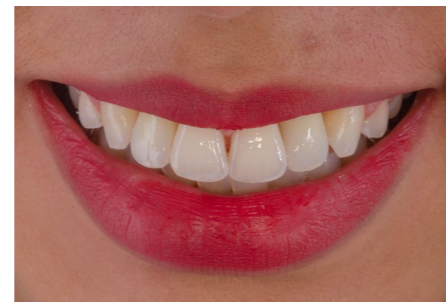The 3D-Xray demonstrates the sub optimally placed implants.



Nine months after removal of the old implants and three months after placement of the new implants. Scan of the new implant position with scan posts.

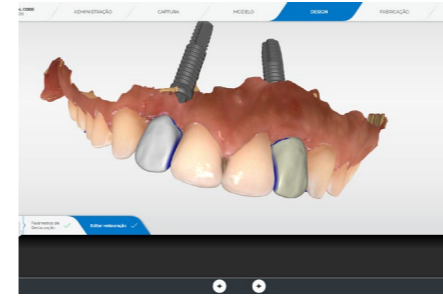

Final restoration of teeth 12 and 22.



Final situation

Workflow Images



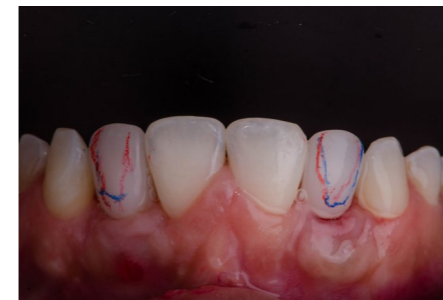Design of the crowns in the CEREC Software.



Milled zirconia abutment.



Adjustment of the CELTRA DUO crown on the InCoris meso abutment.



Marking for the esthetic adjustment of the crowns.